

A Case Report of Open Globe Injury with Iris Prolapse in a Geriatric Patient

MOHAMMED ARIF KADERI¹, SACHIN VISHWANATH DAIGAVANE²



ABSTRACT

To maintain the visual potential of individuals with open globe injuries, anatomical integrity must be restored. Preventing further tissue damage and preserving corneal shape to reduce the resulting postoperative astigmatism are the major goals of initial repair surgery. We present a case of 70-year-old male patient reporting to the OPD of Department of Ophthalmology, with the chief complaint of pain, diminution of vision in left eye and dropping of the left eyelid since two days, due to trauma from bull's horn. The patient was diagnosed with aphakia/open globe injury and underwent three surgical procedures for the rectification of complaint. First procedure was globe injury tear repair, second was scleral tuck lens implantation and finally scleral tuck lens explantation with reimplantation. The three surgeries took place till two months after reporting of the chief complaint.

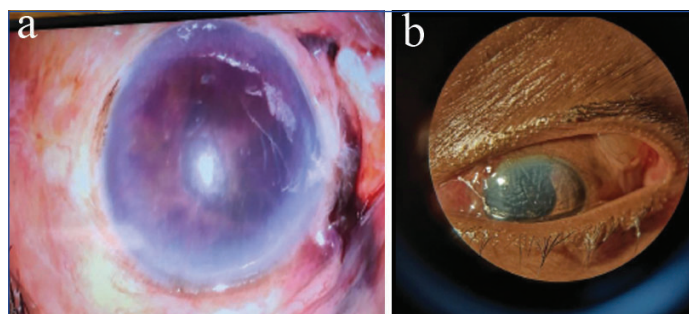
Keywords: Aphakia, Iris injuries, Lens dislocation, Penetrating ocular trauma, Scleral injuries

CASE REPORT

A 70-year-old male patient presented to the OPD of Department of Ophthalmology, with the chief complaint of pain, diminution of vision in the left eye and drooping of the left eyelid since two days after being hit by the bull's horn. The patient experienced discomfort, reduced vision, with drooping of the left eyelid following injury. The damage occurred directly to the left eye, and the patient instantly experienced discomfort and oedema. Over the next several hours, the patient's vision in the left eye gradually decreased, accompanied with ptosis. There was no documented loss of consciousness, bleeding from the eye, or double vision. The patient denied having experienced comparable incidents in the past. There was no history of eye surgery or any serious ophthalmic conditions. The symptoms persisted without relief, necessitating medical evaluation.

On the first visit, the B-scan of the left eye revealed that there was no hyperechoic membrane in the posterior vitreous and the retina was attached. The patient underwent routine examination, which revealed vision limited to hand movements close to the face, with perception of light present and accurate projection of rays. The eyelid showed traumatic ptosis, while the conjunctiva revealed chemosis and congestion. The sclera revealed a tear from the 8 o'clock position to 10 o'clock position [Table/Fig-1a]. Anterior chamber depth was shallow with 2 mm hyphema present, iris tissue was prolapsed from the scleral tear and iridodialysis was present superiorly. The pupil was irregular in shape along with aphakia. Subsequently, lens nucleus was found as a phacocoele in the supero-temporal subconjunctival space [Table/Fig-1b]. Slit lamp examination was done to confirm the above-mentioned findings. Fundus examination revealed hazy media, with the optic disc appearing indistinct due to corneal oedema. A final diagnosis of open globe injury with aphakia was established. The patient underwent routine blood investigations in preparation for surgery. Over a period of two months, he underwent three procedures: primary globe injury tear repair on the first visit, followed by scleral tuck lens implantation, and subsequently scleral tuck lens explantation with reimplantation.

The first surgery was done under local anaesthesia- scleral tear repair was done in the left eye under guarded visual prognosis. The patient had a scleral tear, which was repaired using five interrupted



[Table/Fig-1]: a) Shows the scleral tear with the prolapsed iris tissue through it; b) Shows the phacocoele as described in the text above.

10-0 nylon scleral sutures. The scleral sutures were then covered with two interrupted 10-0 nylon conjunctival sutures. Anterior chamber wash was done to clear the hyphema. The dislocated lens (phacocoele) was cut open by giving a nick on the conjunctiva. Anterior vitrectomy was done prior to closure. Intracamerally moxifloxacin was used. The anterior chamber was formed and the scleral sutures were intact. On postoperative day 1, the cornea showed oedema, while the anterior chamber contained vitreous with iris pigment dispersion. Traumatic aniridia from the 8 to 1 o'clock position was also noted. Oral antibiotics and steroids and topically moxifloxacin (0.5%) and atropine (1%) were prescribed and follow-up was scheduled after seven days.

The second surgery was scheduled one month later under local anaesthesia in which scleral tuck lens implantation was done in the left eye under guarded visual prognosis. The patient had a vision of counting fingers at 0.5 meters distance on the day of discharge. The patient was started on combined steroid and antibiotic eye drops, along with saline 5% eye drops, and atropine 1% was continued. He was also advised to use black goggles and was recalled after seven days for follow-up.

On the third follow-up examination, the scleral tuck lens was found to be decentered. Under local anaesthesia, scleral tuck lens explantation was performed, followed by reimplantation in the left eye, with a guarded visual prognosis. The patient was under observation for four days and was discharged on the same medications. At the time of discharge, his visual acuity was 6/60, and the intraocular pressure was 7 mmHg. The patient was started on oral prednisolone 40 mg once daily for five days, which was

then gradually tapered to 30 mg, 20 mg, and 10 mg once daily, each for five days. He was also prescribed tablet vitamin C 500 mg twice daily, along with topical medications including prednisolone acetate 1% eye drops hourly, moxifloxacin 0.5% eye drops four times daily, homatropine 2% eye drops twice daily, and timolol 0.5% eye drops twice daily.

The patient returned for postoperative follow-up at seven and 15 days, during which no additional complications were observed and reported.

DISCUSSION

One major contributor to visual morbidity is ocular trauma. The vitreous cavity is where crystalline lens dislocation happens most frequently. A phacocoele is the occasional extrusion of the crystalline lens into the space of the subconjunctiva or subtenon as the consequence of indirect scleral rupture brought on by physical trauma. Fejer reported the first instance in 1928. Phacocoele is uncommon and has just been documented a few decades ago [1].

Superonasal dislocation is the most frequent, followed by inferior and superotemporal dislocation. According to Arlt's idea, blunt trauma increases the equator's diameter relative to the line of impact while also decreasing the line of impact's diameter. The third most frequent location for these injuries is the spiral of Tillaux, which is directly posterior to the scleral rupture. Although it has been seen in children as young as 11, it often affects people over 40 since a stiff sclera and a well-formed crystalline lens are thought to be criterion for the condition [2]. It can happen after minor eye injuries that have been treated with surgery in the past or when systemic illnesses cause the sclera to weaken [3,4].

Retinal tears and retinal detachment may be linked to posterior phacocoele because of the posterior position of scleral rupture. Retinal detachment surgery, scleral tear repair, and displaced lens removal are all part of the complicated therapy. Visual results might vary. Only two of the eight patients in Bhattacharjee K et al., case series with traumatic anterior phacocoele were able to attain a final visual result of 20/20 [2]. Traumatic individuals are more likely to develop synechia between the anterior capsule and iris following cataract excision, and synechiolysis may be required for secondary Intraocular Lens (IOL) installation [5]. To determine the best time for secondary IOL implantation, adherence to treatment and follow-up is essential. The timing of cataract removal and IOL implantation are the most often debated topics in these kinds of instances [5,6]. According to reports, a secondary IOL implantation scheduled after the eye's irritation has subsided following first surgery can provide insight into the visual prognosis. According to Rumelt S and Rehany U, the timing of IOL implantation should be determined for each patient individually and based on the surgeon's experience. They also found that IOL implantation time had no influence on postoperative visual acuity in adult patients [5]. To our knowledge, He T et al., conducted the sole investigation on secondary implantation of an IOL time in aphakic patients with open globe damage that has been published in the literature [7]. According to their findings, a waiting period of approximately 2.8 months is recommended between pars plana vitrectomy for open globe injury and secondary IOL implantation to correct aphakia. It would also be more accurate to base the decision to implant an IOL on the retina's anatomical and functional state following pars plana vitrectomy. According to He Y et al., there was no discernible difference in the amount of time needed for visual rehabilitation in aphakia between vitrectomy as well as secondary IOL implantation. The time to do IOL implantation in

this study was 3.79 months after removing issues that might negatively impact the procedure, including the removal of corneal sutures, enhancement of corneal biomechanics, and decrease in inflammation [7].

Xie H-N et al., presented a case of traumatic forces causing complete dislocation of the iris into the vitreous cavity while the lens remained intact. The patient had pars plana vitrectomy to remove the iris, preventing proliferative vitreoretinopathy and subsequent glaucoma. The patient initially opted for non-surgical treatment, but artificial iris implantation was recommended [8]. Recent reviews and multicentre studies undertaken by Zhou Y et al., and Greenfield JA et al., have studied outcomes in open-globe injuries and provided information on how to manage iris prolapse. They discuss critical management tactics, like when to reposition the prolapsed iris, when limited resection is suitable, the best time for surgical repair, and how to utilise viscoelastic agents to safely restore viable tissue to the anterior chamber. These articles also discussed the involvement of the iris, lens, or posterior segment affects visual prognosis [9,10]. Such research is useful for building your geriatric cases since this supports the predicted results and suggested surgical techniques.

CONCLUSION(S)

Early surgical intervention is still the cornerstone of addressing open-globe injuries, since prompt repair minimises the risk of postoperative endophthalmitis and improves long-term visual results. A thorough initial examination, accompanied by proper imaging, is required to precisely establish the amount of eye injury and select the best surgical strategy. The degree and type of the main damage heavily influence the anatomical prognosis, functional recovery, as well as the feasibility or timing of later intraocular lens implantation. Tailored surgical decision-making, along with close postoperative monitoring, improves both structural repair and visual rehabilitation. This thorough, patient-centered approach is critical for attaining the best potential results after traumatic open-globe injuries.

REFERENCES

- [1] Sindal MD, Mourya D. A rare case of traumatic posterior phacocoele with retinal detachment. *Indian J Ophthalmol.* 2016;64(1):89-90. Doi: 10.4103/0301-4738.178165.
- [2] Bhattacharjee K, Bhattacharjee H, Deka A, Bhattacharyya P. Traumatic phacocoele: Review of eight cases. *Indian J Ophthalmol.* 2007;55:466-68. Doi: 10.4103/0301-4738.36487.
- [3] Foroutan AR, Gheibi GH, Joshaghani M, Ahadian A, Foroutan P. Traumatic wound dehiscence and lens extrusion after penetrating keratoplasty. *Cornea.* 2009;28:1097-99. Doi: 10.1097/ICO.0b013e3181a1645e.
- [4] Sharma Y, Sudan R, Gaur A. Post-traumatic subconjunctival dislocation of lens in Ehlers-Danlos syndrome. *Indian J Ophthalmol.* 2003;51(2):185-86.
- [5] Rumelt S, Rehany U. The influence of surgery and intraocular lens implantation timing on visual outcome in traumatic cataract. *Graefes Arch Clin Exp Ophthalmol.* 2010;248:1293-97. Doi: 10.1007/s00417-010-1378-x.
- [6] Sen P, Shah C, Sen A, Jain E, Mohan A. Primary versus secondary intraocular lens implantation in traumatic cataract after open-globe injury in pediatric patients. *J Cataract Refract Surg.* 2018;44:1446-53. Doi: 10.1016/j.jcrs.2018.07.061.
- [7] He T, You C, Chen S, Meng X, Liu Y, Yan H. Secondary sulcus-fixed foldable IOL implantation with 25-G infusion in patients with previous PPV after open-globe injury. *Eur J Ophthalmol.* 2017;27:786-90. Doi: 10.5301/ejo.5000963.
- [8] Xie HN, Chen LL, Wang R, Zhu ZH, Huang HB. Traumatic dislocation of the iris into the vitreous cavity with intact lens: A case report. *BMC Ophthalmol.* 2023;23:105. Doi: 10.1186/s12886-023-03105-x.
- [9] Zhou Y, DiScialfani M, Jeang L, Shah AA. Open globe injuries: Review of evaluation, management, and surgical pearls. *Clin Ophthalmol.* 2022;16:2545-59. Doi: 10.2147/OPHTH.S372011.
- [10] Greenfield JA, Malek DA, Anant S, Antonietti M, Jammal A, Casella A, et al. A multi-center analysis of visual outcomes following open globe injury. *Sci Rep.* 2024;14:16638. Doi: 10.1038/s41598-024-67564-y.

PARTICULARS OF CONTRIBUTORS:

1. Postgraduate Student, Department of Ophthalmology, Jawaharlal Nehru Medical College, Datta Meghe Institute of Higher Education and Research, Wardha, Maharashtra, India.
2. Professor and Head, Department of Ophthalmology, Jawaharlal Nehru Medical College, Datta Meghe Institute of Higher Education and Research, Wardha, Maharashtra, India.

NAME, ADDRESS, E-MAIL ID OF THE CORRESPONDING AUTHOR:

Mohammed Arif Kaderi,
Postgraduate Student, Department of Ophthalmology, Department of
Ophthalmology, AVBRH Hospital, Sawangi, Wardha, Maharashtra, India.
E-mail: mkad11@hotmail.com

PLAGIARISM CHECKING METHODS: [\[Jain H et al.\]](#)

- Plagiarism X-checker: Jul 29, 2025
- Manual Googling: Jan 30, 2026
- iThenticate Software: Feb 02, 2026 (1%)

ETYMOLOGY: Author Origin**EMENDATIONS:** 6**AUTHOR DECLARATION:**

- Financial or Other Competing Interests: None
- Was informed consent obtained from the subjects involved in the study? Yes
- For any images presented appropriate consent has been obtained from the subjects. Yes

Date of Submission: **Jul 15, 2025**Date of Peer Review: **Nov 18, 2025**Date of Acceptance: **Feb 05, 2026**Date of Publishing: **Jun 01, 2026**